



The Outlet

NEW ZEALAND STOMAL
THERAPY NURSES

IN THIS ISSUE:

MARY VENDETTI, A NURSING
LEGEND HAS RETIRED

ISABELLA'S STORY:
A CASE STUDY ON HER JOURNEY

NAVIGATING INDEPENDENCE WITH A
NEW STOMA AND SEVERELY IMPAIRED
VISION: IS IT POSSIBLE?

—
MARCH 2025



AUSTRALIAN ASSOCIATION OF STOMAL THERAPY NURSES

44TH AASTN CONFERENCE

Making Every Connection Matter

**30 APRIL – 2 MAY 2025
PULLMAN MELBOURNE
ON THE PARK**

[CLICK HERE TO ACCESS THE WEBSITE](#)

OR SCAN BELOW



The Outlet

NEW ZEALAND STOMAL
THERAPY NURSES

CONTENTS

PROFESSIONAL SECTION

- 04 EXECUTIVE COMMITTEE MEMBERS
- 05 CHAIRPERSON'S REPORT
- 06 NURSE PROFILE – FREIZZA BELLE PINTO-CAPISTRANO
- 08 EDITORS' REPORT
- 09 MARY VENDETTI, A NURSING LEGEND HAS RETIRED
- 22 WRITING IN THE OUTLET
- 23 AWARDS & GRANTS
- 24 PATRICIA BLACKLEY POSTGRADUATE EDUCATION SCHOLARSHIP
- 28 POLICY FOR BERNADETTE HART AWARD
- 29 APPLICATION FOR BERNADETTE HART AWARD

EDUCATIONAL SECTION

- 11 ISABELLA'S STORY: A CASE STUDY ON HER JOURNEY
- 15 NAVIGATING INDEPENDENCE WITH A NEW STOMA AND SEVERELY IMPAIRED VISION: IS IT POSSIBLE?
- 20 COMBINING SKIN HEALTH AND SECURITY TO MANAGE IRRITATED PERISTOMAL SKIN

ENCOURAGING MEMBERSHIP

EASY MEMBERSHIP SUBSCRIPTION CAN NOW BE GAINED ON THE WEBSITE

www.nzno.org.nz

IF YOUR ADDRESS HAS CHANGED PLEASE CONTACT

Maree Warne | Email: maree.warne@hbdhb.govt.nz

Your Executive Committee Members

COMMITTEE CONTACT



CHAIRPERSON

Maree Warne MNSc
Clinical Nurse Specialist | Ostomy Service
Te Matau a Māui Hawke's Bay
Email Maree.Warne@hbdhb.govt.nz

SECRETARY

Bronwyn MacKenzie
Colorectal CNS
Email: bmackenzie@schb.health.nz



CO-EDITOR

Erica Crosby
Clinical Nurse Specialist Ostomy
Te Whatu Ora Counties Manukau
Email crosbye@middlemore.co.nz



CO-EDITOR

Preeti Charan
Ostomy Clinical Nurse Specialist
Te Whatu Ora Waitemata
Email Preeti.charan@waitematadhb.govt.nz



COMMITTEE MEMBER & WCET DELEGATE

Cathy Enright
Specialty Clinical Nurse, Stomal Therapy
Te Whatu Ora Health NZ Nelson Marlborough
Email Cathy.enright@nmdhb.govt.nz



TREASURER

Frances Horan
Stomal Therapy Nurse
Nurse Maude, Christchurch
Email: frances.horan@nursemaude.org.nz

ISSN 2324-4968 (Print) ISSN 2324-4976 (Online)

Copyright ©March 2025 by the New Zealand Nurses Organisation College of Stomal Therapy Nursing.

www.nzno.org.nz/groups/sections/stomal_therapy

Disclaimer: The Outlet is the official journal of New Zealand Nurses Organisation College of Stomal Therapy Nursing. The opinions and views expressed in the Outlet are those of the authors and not necessarily those of NZNOCSTN, the editor or executive committee.

Published three times a year by Blacksheepdesign www.bsd.nz

Chairperson's Report

MAREE WARNE



Dear Members

I trust this edition finds you all well.
We have some exciting updates to share as we begin a new year.

We would like to extend our deepest thanks to Jillian Woodall, who has served as Secretary for the past year. Jillian's unique energy and contributions will certainly be missed as she steps into retirement. We wish her all the best in this next chapter!

It is with great pleasure that we introduce Bronnie MacKenzie as our new Secretary. Bronnie's first task will be to represent the College at the NZNO College and Sections Day in March. We look forward to her fresh perspective and are confident she will excel in her new role.

Exciting news: The CSTN Conference for 2026 is officially scheduled for the 5th and 6th of March in Christchurch! Be sure to mark your calendars for what promises to be an eventful and engaging conference. Further details will be shared, as we get closer to the date.

Our committee has been invited to provide input into the Australian College of Nursing's Stomal Therapy Nursing Course. I will be attending their advisory meeting later this month and look forward to sharing my insights in the next edition of The Outlet.

Thanks to your responses to our survey, we are thrilled to send Cathy Enright and Preeti Charan to the AASTN conference in Melbourne later this year. Stay tuned for their reflections on the conference in The Outlet.

We continue our work on updating the National Service and Specification document with the Health New Zealand. The Ministry is planning to review this document this year, and we are proud to support the process and ensure Stomal Therapy services remain aligned with the best standards.

We are pleased to congratulate Freizza Pinto on being awarded the 2024 Coloplast Pat Blakely Scholarship. Our involvement in this award continues in 2025, alongside the Bernadette Hart Award. More details will follow in this edition.

Finally, we plan to celebrate Stomal Therapy week in conjunction with the AASTN 23-29th of June. We are planning some exciting initiatives to spread awareness about stoma care and nursing, and we will be sharing more details with you soon on how you can get involved!

We look forward to another year of collaboration, learning, and progress.

Ngā mihi,
Maree Warne

Nurse Profile

FREIZZA BELLE PINTO-CAPISTRANO
OSTOMY NURSE
TE WHATU ORA, AUCKLAND



I have been a Registered Nurse for 15 years now, 6 years in the Philippines and 9 years here in New Zealand.

I started as an Orthopaedic ward nurse in Middlemore Hospital for 2 years then moved to Emergency Department and worked there for 3 years. From 2022, I ventured to working as a District Nurse of Adult Community Services- Te Whatu Ora, Auckland. There I met very inspiring stomal therapy nurses who have introduced and encouraged me to pursue this path of nursing.

Since then, I have loved the dedication that stomal therapy nurses do for ostomate patients to achieve their set goals in stoma management and improve their quality of life. I valued their perseverance in sorting out peristomal complications. The relationship they form with these patients is amazing as they are well-valued by their clients.

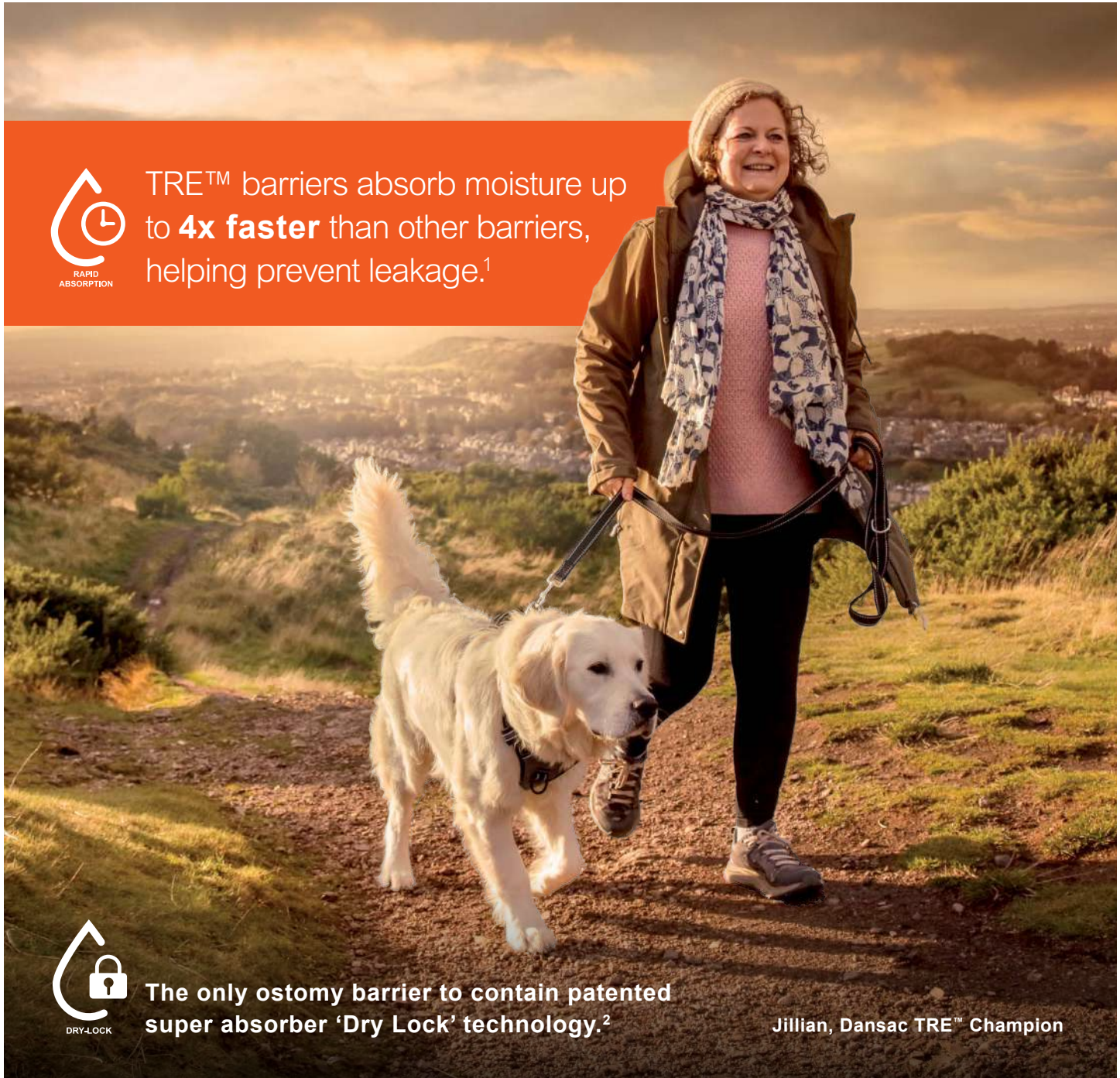I envisioned myself that one day, I can also be an effective and efficient stomal therapy nurse who can assist patients to help them get back to community and do activities that they thought will be difficult to do with a stoma.



Mount Eden, Auckland



TRE™ barriers absorb moisture up to **4x faster** than other barriers, helping prevent leakage.¹



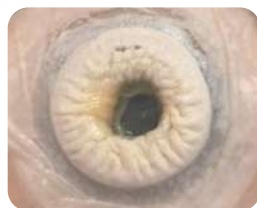The only ostomy barrier to contain patented super absorber 'Dry Lock' technology.²

Jillian, Dansac TRE™ Champion



Before use

Designed to swell & expand, maximising skin contact to form a secure seal for any stoma shape.



After use

The 'rippling' of TRE™ reassures that it is absorbing moisture, without losing strength.

Dansac TRE™
More **confidence** for
you and your patients.

Discover more at:
www.dansac.co.nz
0800 678 669

1. Dansac data on file, LN-06901, 11/24. ref-04051, 2024, Laboratory In Vitro Study using water *In comparison to Coloplast Sensura Mio™ barrier, Salts Confidence Be™ barrier, Convatec Esteem™ barrier and Dansac Nova™ barrier.
2. Dansac data on file, LN-06224, 07/22.

Prior to use, be sure to read the Instructions for Use for information regarding Intended Use, Contraindications, Warnings, Precautions, and Instructions. The Dansac logo, NovaLife and TRE are trademarks of Dansac A/S. © 2025 Dansac A/S. DAN076. February 2025.



Editors' Report

ERICA AND PREETI

We hope everybody had a good holiday and enjoyed the time off with their loved ones. Already in Autumn and children are back to school. For most of us, it is business as usual for Health Care Professionals.

Firstly thank you to Jillian Woodall for her hard work as the secretary for the committee. Welcome to Bronnie MacKenzie to join our committee as a new secretary. Thank you to the members for their on-going support for the Outlet and we are looking forward to continued support and working together in 2025.

We would also like to acknowledge all Nurses who work in the wonderful field of Stomal Therapy in NZ for their hard work and dedication towards their patients during the hardship over the last few years. Whether it is a complex stoma or delays in the provision of supplies hopefully each one of us finished the year with a smile, ready to return for a new year with new adventures.

On a much brighter note, committee members Preeti & Cathy are preparing to attend the Australian Association of Stomal Therapy Nurses conference, in Melbourne. This provides an opportunity to build networks with our ostomy colleagues overseas and strengthen our collegial

relationship, please look forward to a report of the conference in a following edition of the Outlet.

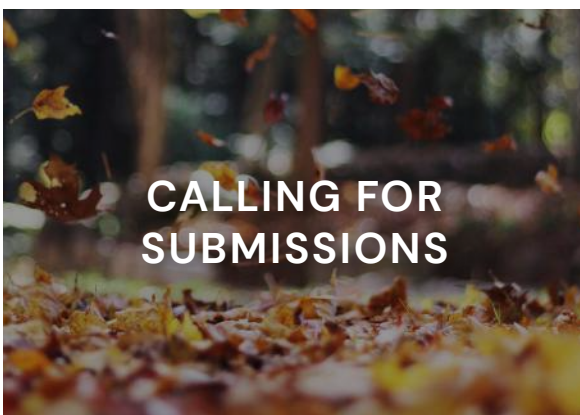
We are fortunate to be in a continuing position to advertise for the awards and grants from which our members can benefit. The funds can be used for conferences and education towards Stomal Therapy Nursing. Please see the criteria for each award/ grant when applying, the details are included in this issue, and on the NZNO CSTN website.

Members can also find the National Clinical Guidelines, and the Stomal Therapy Knowledge Skills & Framework Resources available free for use.

We will continue to provide an update on coming up projects the NZNOCSTN will be involved in coming months.

Preeti Charan

Erica Crosby



CALLING FOR SUBMISSIONS

We know there are A LOT of patients that have benefitted from the expertise and persistence of Stomal Therapists or those nurses with an interest in caring for people with a stoma or fistula. WE WANT YOUR STORIES for this journal. Spread your good work for the benefit of others. We would LOVE to hear from you. Please send your submissions to either:

Please send your submissions to either:

- Preeti.charan@waitematadhb.govt.nz or
- Erica.Crosby@middlemore.co.nz

Mary Vendetti, a nursing legend has retired

BY MARIE BUCHANAN

How do we say thank you and good-bye to someone who has been involved in the field of Stoma Therapy Nursing (STN) for over 25 years?

Mary Vendetti is one of the original or "dinosaurs", (said with love and respect), and has been a member of the STN family for over twenty years. Her peers and patients will miss her knowledge, skills comradery and care, but wish her all the very best for her retirement.

This acknowledgement is a nob to all the hard work, dedication, kindness and commitment she has given not only her chosen speciality as a STN but prior dedication to nursing and her chosen career of caring and giving to others for 50+ year.

Mary left school at the age of sixteen. Her first employment was as a telephonist/office junior to help support her Mother and siblings. However, she had always wanted to be a nurse and the opportunity arrived to pursue this when she noted an ad in the NZ Herald for a Community Nursing course. Mary applied, was accepted and commenced training at St Helen's Hospital in 1971, graduating as a Registered Community Nurse in 1973. This was followed by a 6-month surgical endorsement and employment at Saint Helens and Middlemore hospitals in the general operating theatres. Then it was off to Melbourne and Sydney to work in obstetrics at Queen Victoria Hospital and operating theatres at the Royal Prince Alfred Hospital - who ever said the brain drain to Oz was new, obviously they had not meet Mary! After Australia, she travelled to the USA and worked as a nurse aid in San Diego for three years.

On returning to Auckland, Mary wanted to further her nursing career as RCN's skill base was restricted and further education was the only way forward to achieve what she wanted to. She enrolled at Manukau Polytechnic graduating as a Registered General Nurse with a Diploma in Nursing in 1991

During the period between 1991 and 1998, she worked between Middlemore and Auckland Hospitals on gerontology, surgical and medical wards.

Her introduction to district nursing at Auckland DHB introduced her to the role of a STN. She acknowledges a great mentor, Meg Wood, who inspired her to pursue

the role of an STN. She encouraged her to complete her Stomal Therapy Certificate, at Wairakei Polytechnic, Rotorua in 2001. She continued for a few years as a DN until Meg retired and Mary stepped in for the next 24 years. Mary worked between the hospital and community over this time until recently when the role changed to community base only.

The current environment within the health services of constant change was very challenging in the later years. While Mary acknowledges change is necessary, some is for the better and some are not so good. She believes that the focus of the patient and staff are not always at the forefront of decisions for change and found this difficult to navigate in the later time of her career. In saying this, she is adamant that she has thoroughly enjoyed her career of nursing and would not change it for anything else.

Upon retiring Mary was employed at Te Whatu Ora, Te Toka Tumai. Her dedication to this role was in excess of twenty-four years.

During this time she sat on the NZNO stomal section, now, NZNOCOSTN, committee 3 times. Helped arrange several conferences, attending and supporting many national and international conferences.

With 50 + years of giving, caring for others with empathy and compassion it is time for Mary to have a well-deserved rest. Enjoy her three grandchildren and take time out for herself.

On behalf of the NZNOCSTN, I wish to thank Mary for her dedication, time and commitment to the role of nursing/STN. We wish her all the very best in your retirement.

"Ngā mea tino pai mō te wā heke, me te mihi ki a koe mo to mahi me to whāinga ki te ratonga nēhi"

All the best for the future and thank you for your work and commitment to the nursing service

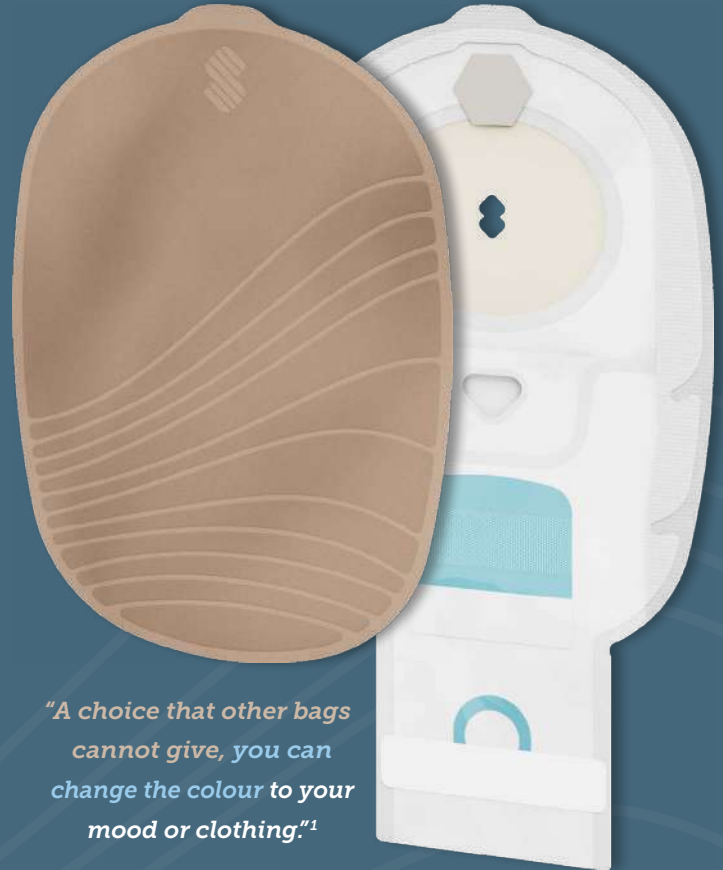INTRODUCING OUR NEW BAG

CONFIDENCE BE go™



Through listening to patients, Confidence BE go™ addresses the unmet needs of people living with a stoma and the clinicians that care for them. For the first time Confidence BE go™ gives your patients the option of a 'naked bag' and a collection of reusable, washable covers in a choice of six colours.

The product is designed to support people living with a stoma with acceptance and quality of life, helping them to feel confident and get back to normality. With the flexibility and freedom to suit any outfit, activity, or mood, your patients can truly express themselves and live life to the full.



"A choice that other bags cannot give, you can change the colour to your mood or clothing."¹

Closed and drainable bags are available with flat and soft convex wafers and a choice of six different covers.

It's as easy as 1,2,3

- 1 ATTACH THE NAKED BAG**
securely to the body
- 2 INSERT THE TANG**
into the tang pocket
- 3 SECURE THE COVER**
to the bag



For samples or more information:
freephone: **TOLL FREE 0800 100 146**
email: ostomy@ainscorp.com.au
or visit: www.saltshhealthcare.com



Wherever they are, whatever they want to do,
they can go for it with **CONFIDENCE BE go™**



Follow us:



Ainscorp

@ainscorpmedical

Isabella's story: A case study on her journey

BY TAYLOR HARRINGTON,
NICU NURSE

INTRODUCTION

This case study follows Isabella, a complex premature infant whose Neonatal Intensive Care stay was further complicated by a spontaneous perforation, requiring a laparotomy and bowel resection resulting in faltering growth.

PATIENT HISTORY

Isabella was born at 30 weeks + 3 days gestation, weighing 1425 grams. Antenatal scans had identified suspected congenital abnormalities, including a two-vessel umbilical cord, right multicystic dysplastic kidney, bilateral SVC, and an aberrant right subclavian artery. Additionally, there was significant polyhydramnios (excess amniotic fluid), raising suspicion of duodenal atresia. An amniocentesis was performed and her microarray and FISH results were normal. Despite her early arrival, Isabella was born in good condition and was breathing on her own. She required brief stabilisation with mask CPAP and oxygen during her transition to extrauterine life, but was weaned off and quickly transported to NICU self-ventilating in room air. Her weight was around the 66th centile for her gestation. During her birth examination, an anorectal malformation was also noted. Given this finding, along with her other congenital anomalies, it became evident that Isabella likely had VACTERL association—a complex condition defined by a group of congenital defects that tend to occur together, however each case is unique.

Isabella was admitted to the NICU for further investigations and management of her prematurity after developing mild respiratory distress. Under normal circumstances, she would have been placed on CPAP. However, due to her anorectal malformation and suspected duodenal atresia, the NICU and surgical teams agreed that elective intubation was the preferred approach. This decision aimed to prevent unnecessary air entry into her gastrointestinal system from CPAP's positive pressure, which could lead to aerophagia, exacerbating her condition and causing significant discomfort. She was electively intubated and received a dose of surfactant to support her lung function. A chest X-ray confirmed appropriate endotracheal tube (ETT) placement and revealed the classic 'double bubble' sign of duodenal atresia, along with cleaving of the thoracic vertebrae.

Plans were promptly made for surgery, including a duodenoduodenostomy and colostomy formation.

On day of life (DOL) 1, Isabella underwent a laparotomy to repair her duodenum and form a colostomy. During the operation, the surgical team found a grossly dilated proximal duodenal bulb with distal collapse of the small bowel. The duodenal atresia was confirmed and resected, with no other atresias noted further along the bowel.

A colostomy was formed just distal to the peritoneal reflection of the left colon, along with a distal mucous fistula for later contrast studies. The surgeons also noted that the colon wall was very fragile. After surgery, Isabella was transferred back to NICU, where she received 48 hours of antibiotics for gut and surgical cover.

She recovered well postoperatively and remained ventilated for eight days before being extubated to high-flow (HF) support. Trophic feeds were started on DOL 4 and were gradually increased to full enteral feeds of 180 mL/kg/day of fortified expressed breast milk (FEBM) by DOL 17.

On DOL 28, corrected gestational age (CGA) 34+3, Isabella clinically deteriorated, developing a firm, distended abdomen with significant mottling and metabolic acidosis. She was made NBM, an IV cannula was placed, and blood work was obtained. An X-ray showed a large amount of free air in the abdomen, indicating a bowel perforation. Isabella, weighing only 1965 grams, was immediately prepared for theatre once again.

SURGICAL HX:

Isabella returned to theatre for her second laparotomy. Her previous wound was reopened and extended. Upon exploring her abdomen, the surgical team encountered dense fibrous adhesions involving the liver capsule and abdominal wall, likely from her prior duodenoduodenostomy. Superiorly, the liver was difficult to release, and some capsular ooze was noted but controlled using a haemostatic agent.

Several soft adhesions were found throughout the bowel, along with a perforation in the mid-distal ileum—approximately 100 cm distal to the D-J flexure and 30 cm proximal to the ileocecal valve. The perforation appeared to be related to an area of adhesional obstruction, however the mesentery also appeared to be kinked and swollen with chyme, potentially contributing. Additionally, Isabella had a large mesenteric defect at the terminal ileum.

A full adhesiolysis was performed to allow visualization of the entire small bowel and correct the mesenteric twist. The perforated section was resected, and a double-barrel stoma was formed. The proximal ileostomy was positioned approximately 100 cm from the D–J flexure, while the distal ileal–mucous fistula was located 30 cm from the ileocecal valve. The exact length of the resected bowel was unclear.

Following the procedure, Isabella was closed and transferred back to NICU, where her parents received the difficult news that her tiny abdomen now had two double-barrel stomas.

ISABELLA'S POST OPERATIVE JOURNEY:

Given Isabella's sudden and significant deterioration preoperatively, her postoperative course was relatively stable. She required a brief period of high-frequency oscillatory ventilation (HFOV) due to a left upper lobe lung collapse but was extubated back to HF postoperative day (POD) 4 and to self-ventilation in room air (SVRA) by POD 9. By this time, her pain was well managed, and she was weaned off her morphine infusion, remaining comfortable on paracetamol.

Following a short period of gut rest, during which she received full total parenteral nutrition (TPN), Isabella was gradually graded back to full enteral feeds of FEBM by POD 5 (DOL 33). Her femoral line that was placed during her laparotomy was removed at this time as it was noted to be leaking with pus surrounding the site. Isabella completed a course of antibiotics for this in consultation with the infectious disease team. Her bloods at this time were not indicative of an infection, but based on her surgical history antibiotic therapy was recommended.

After recovering from her laparotomy and resuming full feeds, Isabella began struggling with weight gain. Once weaned off TPN, she experienced a week of static weight gain despite her ileostomy output being within a normal range (23–28 mL/kg/day). This faltering growth was unexpected, prompting the neonatal team, in collaboration with the dietitian, to consider chyme reinfusion therapy as a plausible treatment option for Isabella.

STARTING CHYME REINFUSION THERAPY USING THE INSIDES® NEO:

At 36+2 weeks CGA (DOL 41), Isabella was started on chyme reinfusion therapy (CRT) using The Insides® Neo. She was POD 13 and weighed 2250 grams.

Isabella had already been using the Hollister Pouchkins™ Newborn Ostomy Pouch prior to her first laparotomy. The flat SoftFlex™ baseplate was very gentle on her preterm skin. After her second surgery, she required two of these ostomy appliances. One on each side of her small abdomen for her two double-barrel stomas. Due to her limited abdominal surface area, the baseplates overlapped and required significant trimming, which initially contributed to frequent leaks.

Once Isabella grew a little bigger, the baseplates no longer needed trimming and could be used as designed, optimizing adhesion and reducing leaks. At her next stoma bag change, her ileostomy bag was fitted with The Insides® Neo chyme reinfusion device. The bedside nurses were able to easily cannulate her ileal mucous fistula using a size 6Fr gastric tube, which was secured at the 5 cm marking with the clip.

Chyme was withdrawn from her ileostomy bag every six hours and reinfused over the following six hours. It wasn't long before her colostomy started producing stool, and soon, her colostomy bag needed emptying too, an exciting milestone in Isabella's refeeding journey!

Throughout her CRT, Isabella's ileostomy output remained within an acceptable range, but more importantly, she began to show a positive growth pattern and consistent, semi-formed colostomy output. She remained on full enteral feeds of 200 mL/kg/day and was even able to start breastfeeding. After just one week, she had gained 190 grams. Everyone, especially her parents, beathed a sigh of relief as she was finally growing again!

Isabella continued her refeeding journey for 32 days. During this time, she kept gaining weight and making progress in areas related to her prematurity. Eventually, she reached a point where she no longer required NICU care and was transferred to the surgical paediatric ward, where she continued CRT while awaiting an anastomosis date.

REANASTOMOSIS AND RECOVERY:

On Day of life 73, 40 weeks + 6 days corrected, weighing 2800 grams, Isabella had her reanastomosis. This was an exciting day for Isabella's parents, as they were one step closer to going home!

She underwent her third and final laparotomy of this hospital stay, during which her ileostomy was reversed. Her surgery went smoothly, and the surgical team also revised her colostomy after discovering adhesions tethering the stomal end to her abdominal wall. Once the colostomy was released and mobilized, it was resutured in place, and Isabella was on her way to recovery.

She required 24 hours of HF support postoperatively and was restarted on small trophic feeds during this time.

WEIGHT GAIN:

In reference to Figure 1, Isabella was born just above the 25th centile for a female preterm infant. After her first laparotomy, during which her duodenal atresia was repaired and a colostomy was formed, her growth began to slow from approximately 32–34 weeks CGA, nearly crossing the 25th centile line before her second laparotomy.

Following her second laparotomy at 34+2 weeks CGA, Isabella initially demonstrated adequate weight gain, likely due to postoperative TPN support. However, TPN was weaned by POD 5, approximately 35+0 weeks CGA. At this time she was back on full enteral feeds. This correlated with a one-week period of relatively static growth before she commenced CRT at 36+2 weeks CGA.

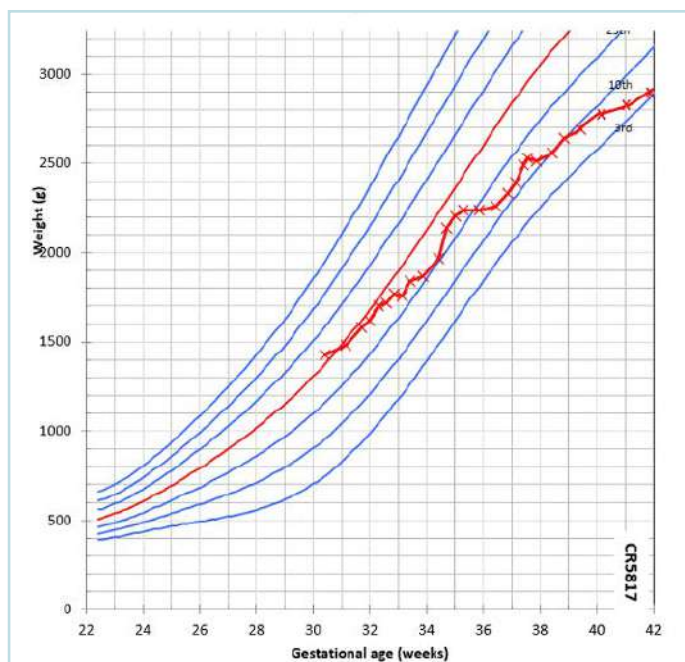


Figure 1

CRT contributed to Isabella’s postoperative growth trends, though it is evident that she continued to struggle with adequate weight gain as she began to cross the 10th centile and approached the 3rd. This happened despite being on feed volumes of 200 ml/kg/day which is the upper limit for neonates with complex cardiac and renal conditions. It could be hypothesized that Isabella’s faltering growth was more closely related to her VACTERL association and other complex medical conditions rather than a direct reflection of bowel function.

Isabella spent a total of 32 days on chyme reinfusion therapy via The Insides® Neo. Her weight gain trends were as follows:

- From birth to her second laparotomy, she gained approximately 19 g/day.
- Following her second laparotomy, she experienced a rapid increase in weight gain over a 7-day period to 38 g/day.
- Once TPN was discontinued, her weight gain significantly slowed to an average of 2 g/day over the next 7 days.
- After initiating CRT, her weight gain stabilized at 26 g/day—slightly better than her pre-deterioration daily average and a marked improvement from her period of static growth.

ISABELLA’S JOURNEY HOME:

After Isabella’s reanastomosis and recovery, she spent 12 more days in the hospital. During this time, she was gradually transitioned back to full enteral feeds while also working on taking all her feeds via breast and bottle, eventually weaning off her nasogastric tube. Several specialty teams, including neurosurgery, cardiology, and renal, assessed Isabella during this period, cleared her for discharge, and arranged outpatient follow-ups.

On DOL 85, CGA 43+1, Isabella’s parents were beyond excited to finally take her home and return to a semi-normal life with their family.

Isabella’s mum, Danielle, and dad, Andy, spent three months in the hospital at Isabella’s bedside, far from their home and support network, which was three and a half hours away. Eventually, Andy had to return to work and was only able to stay on weekends. Meanwhile, Danielle and Andy also had a two-year-old daughter, Olivia, who was adjusting to being away from her parents—though she loved spending time with her cousins and grandparents! She would visit on weekends and was completely entranced by her baby sister, though the NICU environment wasn’t the most exciting place for a toddler.

Danielle and Andy demonstrated incredible resilience throughout Isabella’s journey. After receiving the difficult news antenatally that their daughter could have congenital birth defects, later confirmed as VACTERL association following her preterm delivery, they had to watch their fragile, premature baby undergo her first surgery at just one day old. Just as they were coming to grips with caring for a medically complex child with a stoma, one they thought she would have for at least a year, Isabella surprised them with a second surgery and yet another double-barrel stoma.

Despite these challenges, Danielle and Andy took everything in their stride, remaining strong advocates for their daughter. Now, as Isabella approaches her first birthday, she continues to face the struggles of a medically complex child, particularly with weight gain, remaining below the second centile. However, she has thrived at home, her development flourishing thanks to the love and support of her big sister. Danielle and Andy continue to be fierce advocates for Isabella, and their story is nothing short of inspiring.

CONCLUSION

In conclusion, Isabella, a medically complex baby, spent a total of 32 days using The Insides® Neo after undergoing two laparotomies. She experienced a period of static growth prior to starting chyme reinfusion therapy, but began gaining weight again once The Insides® Neo was introduced. After a long, three-month hospital stay, she was discharged home to be with her family, where she continues her complex medical journey. With the unwavering support of her family, Isabella is thriving.

Say “hello” to more confident living



Preparation



Application



Security



Removal

As many as **75% of ostomates** report skin complications.¹ **Convatec is your solution.**

...with our specially designed range of ostomy skincare accessories

- ✓ Everything you need to build a skincare routine tailored to your needs, while caring for and protecting your skin
- ✓ Our comprehensive range spans preparation, application, security and removal
- ✓ Covering leak protection, to odour control and Sting-Free Skincare, our range helps you say “Hello, World” with the confidence you deserve



For more information or to obtain a FREE sample, please call **0800 225 4309** or email connection.nz@convatec.com

Always read the label and follow directions for use.

1. Salvadalena et al. “Lessons Learned About Peristomal Skin Complications Secondary Analysis of the ADVOCATE Trial”. J Wound Ostomy Continence Nurs 2020;47(4):357-63. ©2023 Convatec Inc. All trademarks are the property of their respective owners. AP-64644-AUS-ENG-v2 O640 September 2023

Navigating Independence with a New Stoma and Severely Impaired Vision: is it possible?

BY LORRAINE ANDREWS
CLINICAL NURSE SPECIALIST-OSTOMY,
ADULT COMMUNITY SERVICES(AUCKLAND)

INTRODUCTION

With the objective of mitigating the potentially severe or even fatal consequences of an anastomotic leak, formation of a de-functioning ileostomy is a frequent sequela of colorectal surgery.

The burden of a de-functioning ileostomy can be significant. Two thirds of patients report diminished QOF and/or morbidity¹.

The timeframe to stomal reversal, a procedure which is not without risk, can become the patient's² primary focus. This focus can impede rehabilitation post the index procedure. The ideal timing to reversal of a de-functioning ileostomy remains the focus of ongoing debate³.

This case study presents Austin's journey through a torturous surgical pathway to his recovery post reversal. Austin is legally blind.

Austin's journey highlights what can be achieved to improve quality of life through a partnership that valued his strengths and life experience.

CONFLICT OF INTEREST

The writer has no conflict of interest to declare.

CONFIDENTIALITY

Austin has consented to the publication of his journey. It is his wish that this presentation will inspire others with the hope that they can live their best life with a stoma and a disability.

Austin has elected not to use a pseudonym. Pseudonyms have been utilised for all other participants in Austin's story.

WHO IS AUSTIN?

Austin is a 61-year-old New Zealander. He was born in Taihape and is the youngest of six children. When Austin was 11 years old, the family moved to Whakatane where his father worked in a garage. Over a period of five months when Austin was 12 years old, he lost his sight due to Hereditary Optic Neuropathy (HON). He was assessed as legally blind and became a resident of Homai College for the blind for the next four years. Austin returned regularly to the family home during holidays.

Subsequent to Austin's loss of vision, two other siblings have become visually impaired. Austin is aware of two cousins and one aunt who have also lost their vision due to HON. To date none of the family's third generation, his nieces and nephews have been effected by HON.

After his time at Homai, Austin moved to Auckland where he worked in a nursery, a bin yard and at Eta foods. He then moved to Lotus manufacturing where he worked for the next 26 years. Austin's memories of his time at Lotus were the outstanding respect and value that he felt from the management. He feels that they were committed to focusing on his abilities rather than his disabilities and ensuring that he was safe in the work environment. This included modifying equipment to accommodate his vision loss and investing the time needed to teach him skills.

Currently Austin lives alone. He lives independently without funded social support. Austin is supported by family, friends and neighbours.

Austin walks long distances using a cane and is confident on public transport. He uses a mobile phone and has friends and neighbours read him text messages.

Austin summarised his attitude to his vision loss with the statement "you have to beat it and live with it or it beats you."

HEREDITARY OPTIC NEUROPATHY (HON)

HON are a group of disorders which cause optic nerve dysfunction/damage. HON is hereditary and based on familial expression⁴.

Features of HON.

- Early age of onset
- Autosomal dominant and maternally carried
- Once diagnosed substantial irreparable nerve damage has already occurred
- Optic nerve damage is progressive
- Males are more frequently effected than females with a predominance of 80–90%⁴
- While females can express features of HON they are more likely to be passive carriers
- Other neurological abnormalities associated with HON are cerebellar ataxia, tremor movement disorders, seizures and muscle wasting

Austin has ataxia and an essential tremor.

ESSENTIAL TREMOR (ET)

ET's are caused by interference in the nerve conduction to affected muscles resulting in involuntary rhythmic shaking of either the whole or isolated parts of the body. The condition is most likely to effect the hands, arms, head and eyelids⁵. Austin's ET effects his hands and is kinetic, generally occurring when performing goal-orientated tasks.

PRESENTATION:

Austin presented acutely with right upper quadrant abdominal pain, dizziness, nausea, vomiting and diarrhoea. A flexible sigmoidoscopy identified a lesion suspicious of cancer, however the biopsy sampling was inconclusive. A complete colonoscopy identified and removed 13 polyps. There was a single 20mm polyps 6 cms from the anal verge which was too large to remove via colonoscopy. Histology of this polyp confirmed high grade dysplasia.

Austin's carcinoembryonic antigen (CEA) was elevated at 7.3. His CT scan and MRI did not identify local or distant disease spread.

Post surgery histology was pT1NO.

SURGERY

- Austin underwent a low anterior resection with formation of a de-functioning loop ileostomy.
- Day 7 post the index procedure he returned to surgery for early closure of his ileostomy. The potential for Austin's vision limitations to impact on his ability to live independently with an ileostomy was a factor in considering the need for early closure.

- By day 11 Austin was febrile, had a distended abdomen, was vomiting and had peritonitis. He returned to surgery for an emergency laparotomy. The surgical options considered were a permanent colostomy or re-formation of the loop ileostomy with a further attempt at closure in 6 months.

He was discharged from hospital to residential care in a private hospital.

EARLY CLOSURE OF A STOMA

With a reported incidence of 3–26%, an anastomotic leak is not uncommon post low anterior resection.

A temporary loop ileostomy, while having an anastomotic protective benefit is not without risk. Two thirds of patients with an ileostomy post low anterior resection report stoma related morbidity¹. Dehydration, peristomal hernia, peristomal skin breakdown, poor effluent containment, obstruction, reduced quality of life, physical, psychological and social distress are not uncommon features of life with a stoma.

Platell et al⁶ maintains that the majority of patients undergoing colorectal surgery recover without anastomosis complications and therefore formation of an ileostomy could be viewed as an unnecessary source of morbidity.

Early ileostomy closure is generally defined as 2 weeks from the index procedure and before the formation of abdominal adhesions make the abdomen a hostile environment for surgery. Traditional closure of ileostomy between 3–9 month is often further delayed by the need for adjuvant therapy, surgical scheduling and changed clinical needs.

Werner et al³ maintained that when bowel continuity was restored before 150 days, complication occurred in 17% of patients. Restored after 150 days and the complication rate was 32%.

Consistently, the highest risk factor of early closure is post-surgery wound infection 19%^{7,8}. The incidence of post operative ileus and obstruction are significantly reduced with early closure verses traditional timed procedures. Late closure of a de-functioning stoma is associated with a significantly higher incidence of post operative complications. The most prevalent complications post traditionally timed closure are dysfunctional digestive problems such as ileus and low anterior resection syndrome. The most frequently sighted rationale for traditional closure timing is the formation of adhesions.

The optimum timing to closure of ileostomy remains unclear. While current research is inconclusive, early closure appears to be beneficial in a carefully selected cohort of patients.⁷

FIRST ASSESSMENT

The outstanding features of my first contact with Austin were his determination and his self-belief that he could independently manage most, if not all, of his ileostomy care. He was highly motivated to maintain his independence and returning to his own home was his primary motivation. Austin's home was within easy walking distance of the private hospital that he had been discharged to. Austin felt that within the time constraints of a busy hospital ward, only limited attempts could be made to teach him ileostomy cares.

His first assessment detailed the following:

- **Stoma:** pink, moist, protruding 2cms, round in shape
- **Peristomal skin:** Austin had experienced several appliance leaks. He had a full circumference skin erosion extending out at least 10mm from the stoma. His appliance was cut to 50mm while the actual stoma was 38mm. This may have been the cause of the appliance leaks. There were no abdominal creases or contours of concern
- **Template:** 38mm
- **Output:** the appliance was being emptied for Austin 4-5x daily. The output was thick and paste like. Austin was drinking 2 litres of electrolyte daily and had no signs of dehydration
- **Mucocutaneous junction:** intact with no sutures present
- **Appliance in use:** the initial appliance was a cut to fit convex one piece

GOALS OF CARE ESTABLISHED WITH AUSTIN

- Austin correctly recognised that the minimum skill he needed, to achieve any independence was the ability to cleanly empty the appliance.
- As Austin's vision would not allow him to cut out an appliance a pre-cut was needed.
- A two-piece appliance was more likely to be placed accurately by Austin as it allowed him to feel the wetness and texture of his stoma in relation to his skin.
- A modified metri-set infusion chamber was used as a guide to facilitate the accurate placement of the baseplate. The metri-set was the perfect diameter for Austin's stoma. Austin could feel the wetness of his stoma to place the metri-set and then guide the baseplate down the metri-set which was then removed.
- Austin needed to learn how to adhere the adhesive coupling of the pouch to the baseplate.
- We needed to ensure that every appliance change was done with Austin rather than for Austin.
- All equipment was to be set up in a completely consistent manner. Each piece was to be in the same place and the tasks were to be completed in the same order. The set up was photographed so it could be followed by all staff.

RATIONALE FOR SELECTION OF THE SALTS HARMONY DUO FLEXIFIT.

- **Pre-cut range:** The Salts Harmony Duo Flexifit convex has multiple pre-cut sizes from 21-38mm. If Austin's stoma changed shape or size it was critical that we did not have to change to a different product range.
- **Anchoring Notch:** Austin could feel the guiding notch on the baseplate to accurately place the pouch. This was not reliant on him being able to see the notch and he could achieve this despite his essential tremor and his visual limitations.
- **Fluted edging:** the fluted edges allowed the baseplate to mould over Austin's abdomen.
- **The Outlet:** Austin found the length of the outlet made it easy for him to empty and clean.
- **Belt loops:** Austin felt that having a belt in place helped prevent drag on his skin as the pouch filled with effluent, this made him feel more secure.




Figure 1: Salts Harmony Flexifit 2 piece

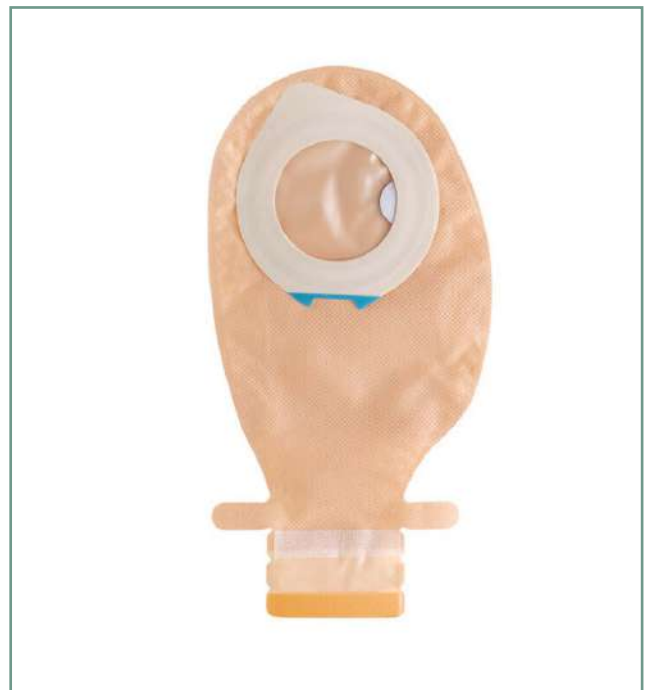

Figure 1: Corresponding Notch on pouch to match notch on baseplate

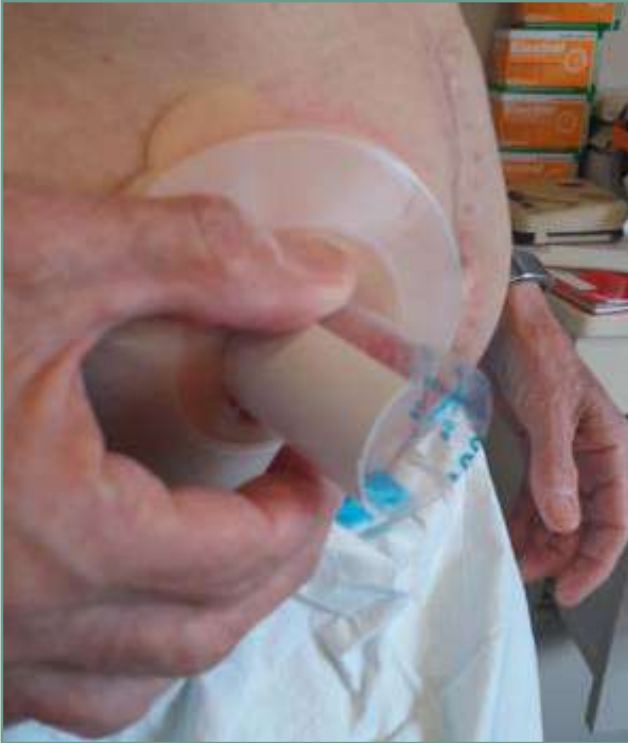

Figure 2: Austin using the modified metri-set chamber to place the baseplate.

Austin achieved independent appliance changes. He left the private hospital early each day and returned at night until his reversal.

REVERSAL OF ILEOSTOMY

Werner³ maintain that reversal of ileostomy after 90 days is associated with a significantly higher rate of post operative complications. Austin went forward for a reversal of his ileostomy 5 months after his second surgery. He subsequently developed low anterior resection syndrome (LARS).

LOW ANTERIOR RESECTION SYNDROME (LARS)

Anastomotic leaks have been sighted as a risk factor for developing major LARS. When not used for prolonged periods, the pelvic floor and sphincter complex resting in a de-functional state, loses strength and fails to contain effluent once reversal of ileostomy has occurred.

Another possible reason for the association between timing of stoma reversal and the development of LARS is the changes in the colonic environment and microbiota which occurs when the bowel is de-functional. Baek et al (2014)⁹ sampled and compared the gut flora of patients with an ileostomy to those without one. They found the abundance of several types of bacteria were markedly different between the research and the control group. They suggested that this could be an explanation for the presence and duration of an ileostomy being influential in the development of LARS and would support early closure.

Six month following stoma closure, Austin's LARS has settled.

CONCLUSION

The available literature on early ileostomy closure may not be entirely conclusive as to what the perfect timing is for the procedure. However, it does indicate there are potentially significant benefits in mitigating the complications of life with a stoma and the complications associated with closure.

A critical factor in Austin achieving success with his ileostomy management was his determination not to let his visual limitations get in the way of him leading a life with maximum independence. A little stomal therapy creativity and working with Austin's abilities rather than letting his disabilities influence and steal his independence led to his success.


REFERENCES

1. Tedman,C. Nguyen,H. Robertson,I. Harvey,X. Tan,B. Tan,M. Yang,C. *Factors affecting timing of loop ileostomy closure: a regional centre's experience with 106 patients.* NZ Journey of Surgery 2024 ;Feb:94(1-2). Pubmed.ncbi.nlm.gov/37876156
2. Coyne,P. Bell,A. Holtham,S. O'Dair,G. *Reversal of Ileostomy: A 4-year study of Morbidity and Mortality.* World Journal of Colorectal Surgery 2014; vol14, issue14:1-7.
3. Werner,J. Kupke,P. Ertl,M. Opitz,S. Schl.H. Hornung,M. *Timing of closure of a Protective Loop ileostomy Can Be Crucial for Restoration of a Functional Digestion.*2022;Mar28;9:p1-27 doi10.3389/furg2022.821509
4. Newman,N. Biousse,V. *Hereditary Optic Neuropathies* Eye 2004;18:1144-1160 Cambridge Potamological Symposium
5. Mayo Clinic Essential Tremors <https://www.mayoclinic.org/disease-conditions/essential-tremor/symptoms-causes/syc-20350534>
6. Platell,C. Barwood,N. Makin,G. *Clinical Utility of a De-functioning Loop Ileostomy.* ANZ Journal of Surgery. 2005;75(3):147-151
7. Robertson,J. Puckett,J. Vather,R. Jaung,R. Bissect,I. *Early closure of a Temporary Loop Ileostomies: A Systematic Review.* Ostomy Wound management 2015;61(5):50-57
8. Omundsen,M. HayesJ. Collinson,R. Merrie,A. Parry,B. Bisset,I *Early Ileostomy closure: is there a downside?* ANZ Journal of Surgery May2012;82,(5),1-6
9. Beck,S. Kim,s. Lee,C. Roh,K. Leym,B. Kim,C. *Relationship between the severity of Diversion Colitis and the Composition of Colonic Bacteria: a prospective study* Gut/Liver 2014;8(2);170-176. Doi10,5009/gnl.2014.8.2.170

**Soft convexity... for when
extra comfort is needed**



ESTEEM® Soft Convex



ALL BODIES ARE DIFFERENT. Esteem®  Soft Convex combines flexibility with a shallow convexity, and is designed to conform well to the body and be comfortable to wear.

Flexible Convexity: conforms to the body and helps improve the pouch seal by minimising leaks

Easy-View Window: for accurate positioning and observation

Filter: designed to help minimise odours and ballooning

Safe Seal Clipless Closure: designed to make emptying and cleaning easy*

For more information or to obtain a FREE sample, please call
0800 225 4309 or email connection.nz@convatec.com

ALWAYS FOLLOW THE DIRECTIONS FOR USE.

*Drainable options only. ® / TM indicate trademarks of the Convatec group of companies © 2024 Convatec Inc. AP-021235.1-NZ O646 June 2024

Combining Skin Health and Security to Manage Irritated Peristomal Skin



Bronwyn Laurie, RN STN, Timaru, New Zealand

Abstract

One crucial goal of the Stomal Therapy Nurse is to help ensure that each patient regains his or her quality of life after surgery. No patient is the same and as such, the evaluation of pouching systems and products to meet an individual's specific needs is imperative in achieving this goal. Skin problems from various reasons, can be a constant issue occurring throughout a patient's lifetime leading to constant skin irritation, pain, itching, leading to skin barriers not adhering, resulting in further leakages. The literature reports that up to seventy-six per cent of stoma patients will experience peristomal skin irritation.¹ This vicious cycle of leakage, skin issues, and associated patient distress are challenging for the clinician but more importantly, for the patient as it impacts their skin health.

The following case study discusses one such patient and her experience with finding a suitable pouching system for her that relies on the mix of skin health and security in achieving her goals of attaining skin health.

Background & Relevant Medical History

Mrs. Q (initial changed to protect privacy) was a seventy-nine year old female with an extensive previous medical and surgical history. She presented with symptomatic sigmoid diverticular disease and an acute chronic inflammation. Surgical intervention was required and Mrs. Q underwent a high anterior resection and formation of a loop ileostomy. She recovered well after surgery with minimal challenges other than some malnutrition. However, she did suffer from mild depression after surgery, which influenced her ability for self-care. Fortunately, her husband was involved in assisting her with her care in the majority.

Challenges

However, she developed a parastomal hernia approximately four weeks after surgery. Prior to developing this hernia, she had not experienced issues with her pouching system. Mrs. Q was quite distressed regarding her pouch dislodging regularly and without warning. The unusual shape of the parastomal hernia and subsequent skin topography appeared to contribute to this.

Her skin was denuded, with some associated peristomal moisture associated skin damage (PMASD) that affected satisfactory adherence of the skin barrier. (See Figure 1) She was experiencing pain coupled with a constant irritation she described as a constant itch. When ongoing, this itch can be difficult to treat and have even more impact on the individual.²

Clinical Management Objectives

Regarding fit, a pouching system was necessary that would move and flex with the body, fit well over the parastomal hernia, not pop off, and ensure extended-wear and comfort. A soft convexity one-piece product was identified as being the most suitable in relation to fit as this could help with addressing many of the topographical challenges.

In terms of formulation, a skin barrier was needed that could provide a feeling of security and comfort, protect the skin's natural moisture balance, and hopefully address her persistent itch. During a recent double-blinded, randomised controlled trial (RCT) of a ceramide-infused skin barrier (CeraPlus Skin Barrier with Remois Technology[®]) vs. a Hollister non-ceramide infused skin barrier, it was reported by patients in the treatment group during this trial, that they were 'very satisfied' with itching prevention.³ Ceramide is a natural component of human skin that helps to decrease transepidermal water loss (TEWL) from damaged or eroded skin.⁴ Putting evidence into practice, it was decided to utilise the CeraPlus[™] skin barrier for this patient.

Lastly, another consideration was the border of integrated adhesive. This helped with the overall flexibility, minimised the need for the clinician to add accessories such as barrier extenders, as well helped to engender a feeling of security, which was expressed by Mrs. Q.

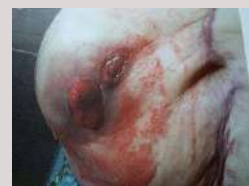

Figure 1 Parastomal Hernia with abdominal bulge (developed 4 weeks post-operatively) and PMASD.



Figure 2 CeraPlus soft convex one-piece pouching system with integrated adhesive border – applied four weeks post-operatively.

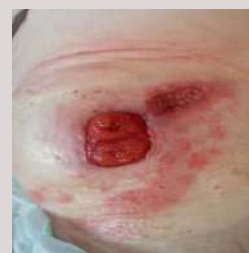

Figure 3 Visible peristomal skin condition improvement within days after pouching system applied.

LEVEL OF EVIDENCE - CASE STUDY

Combining Skin Health and Security to Manage Irritated Peristomal Skin

Outcomes

As noted by the pictures of the progress made once Hollister CeraPlus™ soft convexity pouch was introduced the peristomal skin visually improved within days. (See Figures 2 & 3) The pouch was flexible, moved well with her body shape, sat well over the parastomal hernia and remained well adhered.

With the CeraPlus™ soft convexity pouch remaining insitu, this ensured that the peristomal skin progressed well and continued to visually improve within a matter of days. (See Figure 4) The patient and her husband were calmer and no longer distressed. The patient reported that her peristomal skin caused no irritation, itchiness, or pain. The patient once again was able to go out in comfort, attend church and all activities that she had been missing for fear of the pouch falling off.

Conclusion

Maintaining peristomal skin health is a key challenge for the clinician and the person living with a stoma. The impact of peristomal skin conditions can sometimes create profound impacts on a person's quality of life.⁵ Identifying the correct fit from a pouching system goes a long way in ensuring positive outcomes. However, this is not the standalone factor when considering a pouching system for a patient. During one's clinical decision-making, using evidence to identify and select products regarding formulation in maintaining skin health, is an aspect some clinicians possibly overlook concerning peristomal skin health. This is another important aspect for consideration in maintaining skin health.

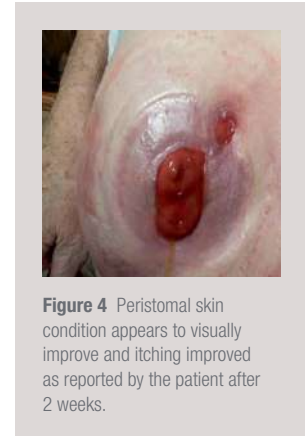


Figure 4 Peristomal skin condition appears to visually improve and itching improved as reported by the patient after 2 weeks.



To learn more about CeraPlus™ Products, click here or scan the QR code



To visit the Hollister website, click here or scan the QR code



To visit the Hollister Clinical Education Website, click here or scan the QR code

1. Richbourg L, Thorpe J, Rapp C. Difficulties Experienced by the Ostomate After Hospital Discharge. J Wound Ostomy Continence Nurs. 2007; 34(1): 70-79
2. Bautista, D.M., Wilson, S.R., Hoon, M.A. (2014). Why we scratch an itch: The molecules, cells and circuits of itch. Nat. Neurosci 17(2): 175-182.
3. Colwell J, Pittman J, Raizman R, Salvadalena G, A Randomized Controlled Trial Determining Variances in Ostomy Skin Conditions (ADVOCATE), J Wound Ostomy Continence Nurs. 2018;45(1):37-42.
4. McPhail, J 2015, 'The role of ceramide in skin function and the understanding of its role in minimising transepidermal water loss (TEWL) in peristomal skin', ASCN UK Poster Presentation, <http://ascnuk.com/wp-content/uploads/2015/12/P-26.pdf> Accessed October 2019.
5. Nichols TR. Quality of life in US residents with ostomies assessed via the SF36v2: Role-physical, bodily pain, and general health domain. J Wound Ostomy Continence Nurs. 2016; 43(3):280-287.



*Contains the Remois Technology of Alcare Co., Ltd.

Prior to use, be sure to read the Instructions for Use for information regarding Intended Use, Contraindications, Warnings, Precautions, and Instructions.

Disclaimer: This case study represents this nurse's experience in using the CeraPlus™ skin barriers with the named patient, the exact results and experience will be unique and individual to each person.

Hollister, the Hollister logo, the Hollister Education logo and CeraPlus are trademarks of Hollister Incorporated. All other trademarks and copyrights are the property of their respective owners. Not all products are CE marked.

© 2025 Hollister Incorporated. AUH349. February 2025.



PO Box 107097,
Auckland Airport,
Auckland 2150
0800 678 669

www.hollister.co.nz

Writing in The Outlet

PURPOSE

The Outlet is the journal representing the New Zealand Nurses Organisation College of Stomal Therapy Nursing (NZNOCSTN), and has a strong focus on the specialty nursing area of Stomal Therapy. Local input is encouraged and supported. The editors of The Outlet are appreciative of the opportunity to assist and mentor first time publishers or to receive articles from more experienced writers. The guidelines below are to assist you in producing a clear, easy to read, interesting article which is relevant.

The main goal of writing for the Outlet is to share research findings and clinical experiences that will add value and knowledge to clinical practice of others. The essence of writing for The Outlet is a story or research study, told well and presented in a logical, straight forward way.

Readers of The Outlet are both generalist nurses and specialist Stomal Therapists. Articles should be focused on what a nurse/patient does; how a nurse/patient behaves or feels; events that have led to the situation or on presenting your research methodology and findings. Linking findings to practice examples often increases comprehension and readability. Addressing questions related to the who, what, why, when, where, and/or how of a situation will help pull the article together.

GUIDELINES

Writing Style

Excessive use of complicated technical jargon, acronyms and abbreviations does not add to the readability of an article and should therefore be avoided if possible. Short sentences rather than long running ones are more readable and generally promote better understanding. The Outlet has a proofing service to assist with spelling, grammar etc.

Construction of the Article

It may help in planning your article if you bullet point the key concepts or points, format a logical paragraph order and then write the article from that plan.

Article Length

There are no word limits for publishing in The Outlet. First time writers may like to limit themselves to 2500-3000 words which is approximately three published pages.

Photographs, Illustrations, Diagrams, Cartoons

These are all welcome additions to any article. Please email these with your article providing a number sequence to indicate the order in which you wish them to appear and a caption for each.

Copyright

The NZNOCSTN retains copyright for material published in The Outlet. Authors wanting to republish material elsewhere are free to do so provided prior permission is sought, the material is used in context and The Outlet is acknowledged as the first publisher. Manuscripts must not be submitted simultaneously to any other journals.

Referencing

The preferred referencing method for material is to be numbered in the body of the work and then to appear in the reference list as follows:

1) North, N.& Clendon, M. (2012) A multi-center study in Adaption to Life with a Stoma. *Nursing Research* 3:1, p4-10

Most submitted articles will have some editorial suggestions made to the author before publishing.

Example Article Format Title

As catchy and attention grabbing as possible. Be creative.

Author

A photo and a short 2-3 sentence biography are required to identify the author/s of the article.

Abstract

Usually a few sentences outlining the aim of the article, the method or style used (e.g. narrative, interview, report, grounded theory etc.) and the key message of the article.

Introduction

Attract the reader's attention with the opening sentence. Explain what you are going to tell them and how a literature review must be included.

Literature Review

If publishing a research paper.

Tell Your Story

Ask yourself all these questions when telling your story. Who was involved, history of situation, what happened, your assessment and findings, why you took the actions you did and the rationale for these? Your goals/plan. The outcome. Your reflection and conclusions. What did you learn? What would you do differently next time?

Remember there is valuable learning in sharing plans that didn't achieve the goal you hoped for.

Patient stories are a good place to start your publishing career and nurses tell great stories. As editors we encourage you to experience the satisfaction of seeing your work in print and we undertake to assist in every way that we can to make the publishing experience a good one.

NB: Written in conjunction with NZNO Kai Tiaki Publishing Guidelines

Awards & Grants

Available to ALL members of NZNOCSTN.

Review full information on NZNOCSTN web site.

Bernadette Hart Award

Section members may make application annually for the Bernadette Hart Award. The award is for conference or course costs. See full history of award on NZNOCSTN web site.

Applications close on 20 July annually.



Congratulations! Patricia Blackley Scholarship 2024

Coloplast in collaboration with the Australian Association of Stomal Therapy Nurses (AASTN) and the New Zealand Nurses Organisation College of Stomal Therapy Nursing (NZNOCSTN) are pleased to award the Patricia Blackley Post Graduate Educational Scholarships 2024 to:

- Yangyang Fan (Brisbane, Queensland)
- Kate Hallett (Port Macquarie, New South Wales)
- Freizza Pinto (Auckland, New Zealand)

Each recipient will receive \$5000 (AUD) to undertake and advance post graduate education in stomal therapy management or a related practice to improve the quality of care for people in Australian and New Zealand.

To learn about the 2025 Scholarship, please contact your local Coloplast Territory Manager



“Continuous professional education allows me to practice my speciality with confidence and efficiency. This scholarship provided an opportunity for me to boost my learning in Ostomy nursing to deliver safe and effective care to all my clients.”

**Freizza Pinto
(Auckland, New Zealand)**



Patricia Blackley Postgraduate Education Scholarships 2025

As proud supporters of professional nursing education in ostomy care, Coloplast Australia and New Zealand (ANZ) are pleased to announce the Patricia Blackley Postgraduate Education Scholarships. These scholarships honour the pioneering work of Patricia Blackley as a clinician, educator, author, and journal editor in stomal therapy nursing.

This educational initiative is being conducted in collaboration with the Australian Association of Stomal Therapy Nurses (AASTN) and the New Zealand Nurses Organisation College of Stomal Therapy Nursing (NZNOCSTN).

Could you be the next scholarship recipient?



Yangyang Fan
(Brisbane)
2024 Recipient



Freizza Pinto
(Auckland)
2024 Recipient



Kate Hallet
(Port Macquarie)
2024 Recipient



Could this be you?
2025 Recipient

"Receiving the 2024 Patricia Blackley Scholarship is a great honour and a pivotal moment in my professional journey. It enables me to further develop my expertise, advance clinical practice in stomal therapy nursing, and contribute meaningfully to improving patient care while making a positive impact on our local ostomy community."

Yangyang Fan (Brisbane, Queensland)

"Continuous professional education allows me to practice my speciality with confidence and efficiency. This scholarship provided an opportunity for me to boost my learning in Ostomy nursing to deliver safe and effective care to all my clients." Freizza Pinto (Auckland, New Zealand)

"I am a strong supporter of further education for Nurses and believe that expanding knowledge within Nursing specialties allows us to provide the best most up to date specialty care to patients and their families."

Kate Hallet (Port Macquarie, New South Wales)

What is the purpose of the scholarships?

- To enable Registered Nurses working in ostomy care to undertake postgraduate education in Stomal Therapy Nursing or a related area of practice.
- To improve the quality of ostomy care for people in Australia and New Zealand by advancing postgraduate nursing education.

What is the value of the scholarships?

- Three scholarships are available. The value of each scholarship is \$5000 Australian Dollars.
- If there are no applicants who successfully meet the selection criteria, the scholarships will not be awarded.

What courses are eligible for the scholarships?

These scholarships may be used to support:

- Course fees for the Graduate Certificate of Stomal Therapy Nursing through the Australian College of Nursing or the Graduate Certificate in Wound, Ostomy and Continence Practice through Curtin University, OR
- Course fees for another post graduate course relevant to Stomal Therapy Nursing practice. For example; Master of Nursing, Master of Advanced Nursing Practice, Master of Counselling, Master of Business Administration, or Master/Graduate Certificate in another relevant skill set.

What is the selection criteria?

Applicants must:

- Be a Registered Nurse with the Australian Health Practitioners Regulation Agency (AHPRA) OR the Nursing Council of New Zealand (NCNZ).
- Be able to provide evidence of being employed in an appropriate clinical setting.
- Have the support of their manager or head of department.
- Be a member of the AASTN or NZNOCSTN or be willing to become a member or associate student member once the scholarship has been awarded and remain a member for the duration of the study program.
- If awarded the scholarship, agree to the public promotion of their success.
- If awarded the scholarship, agree to deliver an education session at an AASTN/NZNOCSTN meeting/conference OR prepare a journal article for the Journal of Stomal Therapy Australia/The Outlet (NZ).

How do I apply?

Please include separate pages in your application for each of the following:

- The completed application form (photocopy last page or visit: www.stomaltherapy.au/scholarships for electronic copy).
- Resume: include your full work history and details of membership/participation in professional organisations.
- A letter of support from line manager including how the furthered education will help the organisation
- Proof of current AHPRA or NCNZ registration as a Registered Nurse.
- Cover letter: include an outline of how you plan to utilise and disseminate the knowledge gained from the course and your anticipated commitment to Stomal Therapy Nursing (up to 300 words).
- Other funding sources: Please give details in your cover letter if you have received funding from any other source.

What are the important dates?

Applications open
1 March 2025



Applications close
30 September 2025



Application outcome
November 2025



Applications must be lodged with the chairperson AASTN Education and Professional Development Subcommittee before the closing date of 30th Sept 2025. Late applications will not be considered. The email address for lodgement is: education@stomaltherapy.au

Frequently Asked Questions

What is the selection process?

Applications will be reviewed by a selection panel comprised of at least two AASTN Education and Professional Development Subcommittee members and at least one member from the NZNOCSTN.

If the selection criteria and guidelines have been met, a short-list of finalists will be agreed by the selection panel, and if necessary, a brief video conference interview will be arranged with each of the short-listed applicants.

The interview will explore the applicant's commitment to the specialty of Stomal Therapy Nursing and how they will use the knowledge gained from the course.

This interview will occur within 6 weeks of the applications closing and will assist the final decision on the scholarship award.

If the existing panel members have a conflict of interest, a maximum of two proxies may be selected from the AASTN Education and Professional Development Subcommittee membership or one proxy from the NZNOCSTN membership.

The decision of the interview panel will be final and applicants will be notified of the result.

When will the scholarships be awarded?

The successful scholarship recipients will be announced by the AASTN and the NZNOCSTN in November 2025.

If awarded the scholarship, the successful applicant must provide to the AASTN Education and Professional Development Subcommittee:

- Confirmation of enrolment in the nominated postgraduate course as soon as possible after enrolment.
- Proof of AASTN or NZNOCSTN membership.
- A copy of the Degree Certificate (testamur) or Statement of Completion of the nominated postgraduate course as soon as is reasonably possible after completion of the course.

Documents should be emailed to: education@stomalththerapy.au

What happens if I am awarded the scholarship, but do not complete the course?

Withdrawal from course or failure to successfully complete the course within a two-year period, unless agreed as below, will require all scholarship funds to be returned to the AASTN or the NZNOCSTN.

Unexpected program interruptions which delay completion will be considered for retaining the financial assistance after written application to the Chairperson of the AASTN Education and Professional Development Subcommittee, outlining the reasons for delay. This should be sent via the email address:

education@stomalththerapy.au

Return of scholarship funds must be made within 30 days of enrolment cancellation or notification of unsuccessful results.

Application form

Patricia Blackley Postgraduate Education Scholarships 2025

Name: _____

Address: _____

Mobile: _____ Work: _____

Email: _____

Place of Employment: _____

Name of Course and Education Institution: _____

Course Commencement Date: _____ Anticipated Completion Date: _____

Applicant Agreement:

- Payment of the scholarship is subject to the successful completion of the nominated course.
- I understand and accept that if I withdraw from the above course for any reason or do not successfully complete the course within a two-year period (unless otherwise agreed), all scholarship funds must be returned to the AASTN/NZNOCASTN within 30 days.
- I understand that I must provide proof of completion to the AASTN Education and Professional Development Subcommittee as soon as is reasonably possible after course completion.
- If awarded the scholarship, I agree to public promotion of my success.
- I agree to deliver an education session at an AASTN/NZNOCASTN meeting/conference OR prepare a journal article for the Journal of Stomal Therapy Australia/The Outlet (NZ).

Applicant's Signature: _____ Date: _____

Manager/Head of Department Endorsement:

I _____, fully endorse the application of _____
_____ for the Patricia Blackley Postgraduate Education Scholarship.

Signature: _____ Date: _____

Position: _____

Facility: _____

This application for together with accompanying documents must be lodged before the closing date of 30th Sept 2025 to education@stomaltherapy.au

Policy for Bernadette Hart Award

PROCESS

- The Bernadette Hart Award (BHA) will be advertised in the NZNOCSTN Journal The Outlet
- The closing date for the BHA applications is 20 July each year
- The NZNOCSTN Executive Committee will consult and award the BHA within one month of the closing date
- All applicants will receive an email acknowledgement of their application
- All applicants will be notified of the outcome, in writing, within one month of the closing date
- The monetary amount of the award will be decided by the NZNOCSTN Executive Committee. The amount will be dependent on the number of successful applicants each year and the financial status of the BHA fund
- The name of the successful applicants(s) will be published in the NZNOCSTN Journal The Outlet
- The BHA Policy will be reviewed annually by the NZNOCSTN Executive Committee.

CRITERIA

- The applicant(s) must be a current member of the NZNOCSTN and have been a member for a minimum of one year
- Successful applicant(s) must indicate how they will use the award. The award must be used in relation to Stomal Therapy nursing practice
- The applicant(s) previous receipt of money (within the last five years) from the NZNOCSTN and/or the BHA will be taken into consideration by the NZNOCSTN Executive Committee when making their decision. This does not exclude a member from reapplying. Previous receipt of the BHA will be taken into account if there are multiple applicants in any one year
- The funds are to be used within 12 months following the receipt of the BHA.

FEEDBACK

- Submit an article to The Outlet within six months of receiving the BHA. The article will demonstrate the knowledge gained through use of the BHA

and/or

- Presentation at the next NZNOCSTN Conference. The presentation will encompass the knowledge/nursing practice gained through the use of the BHA.

Application for Bernadette Hart Award

CRITERIA FOR APPLICANTS

- Must be a current full or life member of the NZNO College of Stomal Therapy Nursing (NZNOCSTN) for a minimum of one year
- Present appropriate written information to support application
- Demonstrate the relevance of the proposed use of the monetary award in relation to stomal therapy practice
- Provide a receipt for which the funds were used

- Use award within twelve months of receipt
- Be committed to presenting a written report on the study/undertaken or conference attended or write an article for publication in The Outlet or to present at the next national conference

APPLICATIONS CLOSE 20 JULY (ANNUALLY)

SEND APPLICATION TO:

Email: emma.ludlow@middlemore.co.nz

BERNADETTE HART AWARD APPLICATION FORM

Name: _____

Address: _____

Telephone Home: _____ Work: _____ Mob: _____

Email: _____

STOMAL THERAPY DETAILS

Practice hours Full Time: _____ Part Time: _____

Type of Membership FULL LIFE

PURPOSE FOR WHICH AWARD IS TO BE USED

(If for Conference or Course, where possible, please attach outlined programme, receipts for expenses if available)

- Outline the relevance of the proposed use of the award to Stomal Therapy

EXPECTED COSTS TO BE INCURRED

Fees: (Course/Conference registration)

\$ _____

Transport: \$ _____

Accommodation: \$ _____

Other: \$ _____

Funding granted/Sourced from other Organisations

Organisation:

_____ \$ _____

_____ \$ _____

_____ \$ _____

PREVIOUS COMMITMENT/MEMBERSHIP TO NZNOSTS

Have you been a previous recipient of the Bernadette Hart award within the last 5 years?

Yes (date) _____

No

Please Indicate ONE of the below: (please note this does not prevent the successful applicant from contributing in both formats).

Yes I will be submitting an article for publication in 'The Outlet' (The New Zealand Stomal Therapy Journal).

Yes I will be presenting at the next National Conference of NZNOCSTN.

Signed: _____

Date: _____

NEW
EXTENDED
RANGE

eakin
freeseal[®]

**NOW
WITH
PRE-CUTS**

YOU ASKED, WE LISTENED

The new extended freeseal[®] range now includes pre-cuts, providing a seal for every body, perfect for every day. Easy to mould, easy to remove, easy to love.

eakin
freeseal[®]
air

3 seals from 1.8mm thin
Barely there feel for
comfort and discretion



eakin
freeseal[®]
versa

2 seals at 3.2mm thick
For use with any pouch,
loved for lumps and bumps



OMNIGON

www.omnigon.com.au

info@omnigon.com.au

AU 1800 819 274

NZ 0800 440 027

UNLOCK THEIR UNSTOPPABLE



The Outlet

NEW ZEALAND STOMAL
THERAPY NURSES



NGĀ MIHI NUI